# *Biopsy and Pathology Thought Process Map*

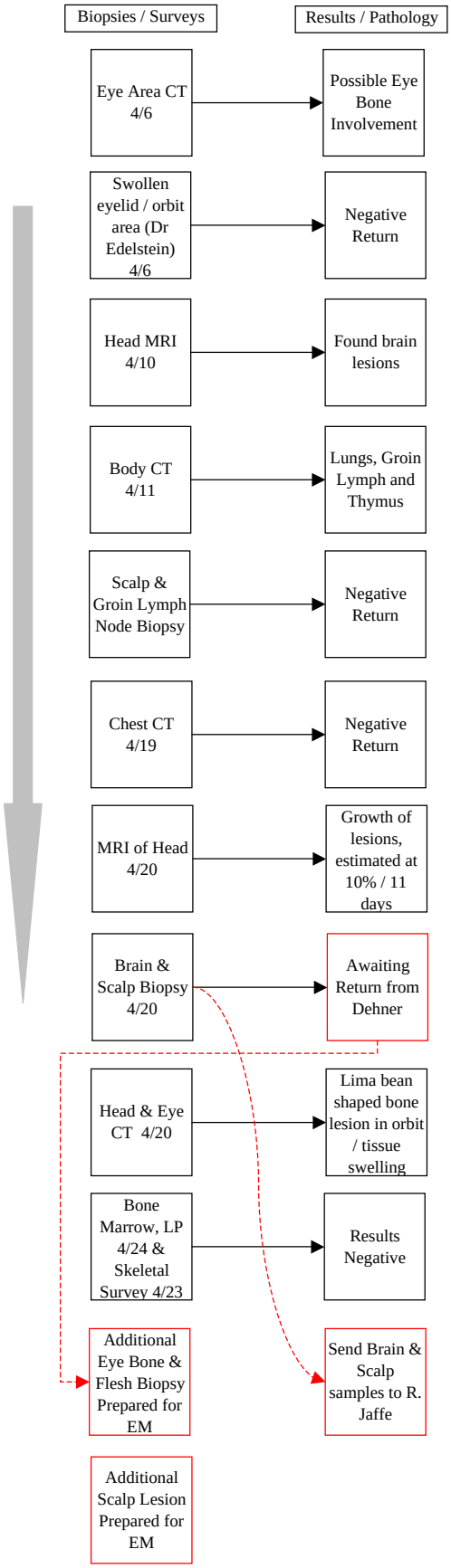


How were the samples taken?
Evaluated for infection only?

How do we know other organs are not involved?

What methodologies were used?
CD1a antigen performed? Result?

Hospital pathology not conclusive, which test were performed?
Concerned with difficult pathology in this area
- Lack of Birbeck Granules under electron microscopy
- Lack of Langerhans Cells (in Brain & Liver - suggest LC not cause)
- Fatty Macrophage presentation (not typical)

Which test were performed on Scalp biopsy